

# COMPARISON BETWEEN TRANSVAGINAL ULTRASOUND AND MAGNETIC RESONANCE IMAGING IN OVARIAN AND DEEP INFILTRATING ENDOMETRIOSIS IN A TERTIARY HOSPITAL.

Carmona Payán P., Muñoz Hernando L., López González G., Puente Águeda JM., Álvarez Conejo C., Lorenzo Hernando E., Oliver Pérez MR., Díez Álvarez A., Bolívar de Miguel AB., Castillo Rabazo LP., Muñoz González JL.  
Hospital Universitario 12 de Octubre, Madrid (Spain).

## INTRODUCTION

Endometriosis is an important entity which affects more than 10% women around the world. There are 3 main endometriosis types: superficial, ovarian and deep infiltrating endometriosis (DIE). DIE is the one that mostly affects quality of life. This is why it is important to reach an accurate diagnosis. The diagnostic accuracy of transvaginal ultrasound (TVS) and magnetic resonance imaging (MRI) is comparable for ovarian and deep infiltrating endometriosis, according to scientific literature. The aim of this study is to compare both of them in our hospital.

## MATERIAL AND METHODS

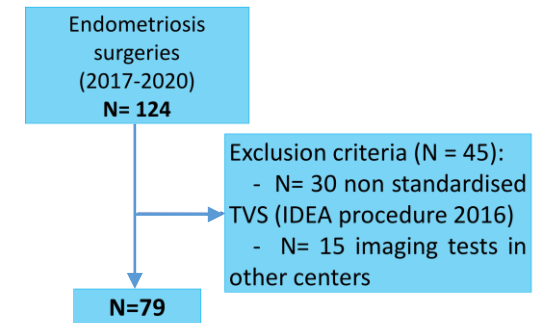
We conducted a descriptive retrospective study in Hospital 12 de Octubre, Madrid (Spain), on patients who underwent endometriosis surgery between 2017-2020. We analyse and compare diagnostic accuracy of MRI and TVS in different locations of deep infiltrating endometriosis comparing with surgery (gold standard of endometriosis diagnosis).

## RESULTS

There was no statistically difference between TVS and MRI in diagnostic accuracy for all locations studied and neither in global deep infiltrating endometriosis diagnosis.

## CONCLUSIONS

In our hospital we have similar diagnostic accuracy between MRI and TVS in ovarian endometriosis and all locations of DIE. Therefore, TVS must be the chosen imaging test to first approximation to ovarian endometriosis and DIE because it is more affordable, cheap and faster to perform than MRI. Uterosacral ligaments location is the one with the lowest accuracy described in literature and the one that requires the TVS longest learning curve.



	Diagnostic accuracy		
	TVS	MRI	P
<b>Global</b>	84.6	85.4	<b>0.91</b>
<b>Ovarian endometriosis</b>	94.9	95.2	<b>0.84</b>
<b>Posterior sliding sign</b>	89.9	97.6	<b>0.25</b>
<b>Rectosigma</b>	88.6	87.8	<b>0.86</b>
<b>Rectovaginal septum</b>	91.1	87.8	<b>0.80</b>
<b>Vagina</b>	98.7	100	<b>&gt;0.05</b>
<b>Urine bladder</b>	97.5	95.2	<b>0.91</b>
<b>Uterosacral ligaments</b>	79.8	80.5	<b>0.92</b>